

# Aneurysm of the Superior Mesenteric Vein: case report

SHAW-NAN JEAN<sup>1</sup> XIAN-JIA JIANG<sup>1</sup> YUNG-FANG CHEN<sup>2</sup> JUI-FEN CHEN<sup>2</sup>

*Department of Radiology<sup>1</sup>, Dachien General Hospital*

*Department of Radiology<sup>2</sup>, China Medical University Hospital*

**Venous aneurysms are uncommon in clinical practice. Idiopathic aneurysms of the superior mesenteric vein are rare. The etiology of these aneurysms is unclear, as they are found in both asymptomatic individuals and in those with concurrent disease. Herein we discuss a case of superior mesenteric vein aneurysm in a patient with colon cancer diagnosed with MDCT.**

Aneurysms of the superior mesenteric vein are rare; the first case was reported by Barzilai and Kleckner in 1956. Many aneurysms are asymptomatic, and the diagnosis is established from radiologic findings. Others are diagnosed after complications such as gastrointestinal bleeding or thrombosis with associated abdominal pain. Because imaging of the abdomen is performed more frequently than ever, such aneurysms may be more common than previously recognized. Herein we present a case with no predisposing factor.

## CASE REPORT

A 64-year-old woman presented with intermittent right lower quadrant pain of one month. Laboratory analysis revealed an elevation of CEA. An abdominal sonogram showed target-sign in the right lower quadrant. Unenhanced and enhanced CT scans demonstrated a mass-like lesion in the right ascending colon and the coronal and the axial section of CT scan showed a dilated (1.8 cm AP) diameter superior mesenteric vein (Fig. 1) without internal thrombosis near the level of the portal confluence (Fig. 2). Surgical intervention was performed for the colon, and the pathology was confirmed as colon cancer. Since the time of diagnosis of the aneurysm, the patient's condition has remained stable and continues to be followed clinically.

## DISCUSSION

The portal vein is created by the confluence of the SMV and splenic veins at the level of the pancreatic neck. It extends into the hepato-duodenal ligament and is divided into the right and left branches to supply both lobes of the liver. Its trunk measures 5 to 7 cm in length. Characteristically, the SMV is located anterior right to the superior mesenteric artery and posterior medial to the head of the pancreas. The SMV tributaries are the ileocolonic, pancreaticoduodenal, & gastroepiploic veins. Normally,

---

Reprint requests to: Dr. Shaw-Nan Jean  
Department of Radiology, Dachien General Hospital.  
No. 6, Shinguang Street, Miaoli 360, Taiwan, R.O.C.

the SMV measures 1.2 cm in diameter [1]. Its size was reported as abnormal if it measured  $> 1.4$  to 1.6 cm in transverse diameter or showed abrupt change of the caliber it courses.

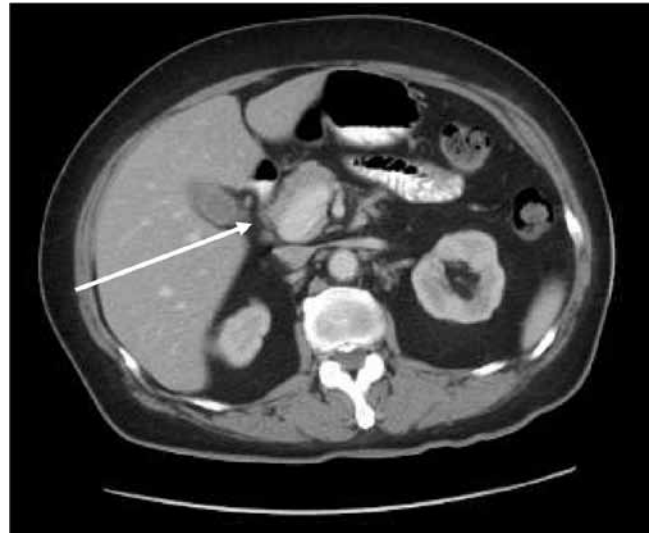Aneurysms of the superior mesenteric vein are rare; the first case was reported by Barzilai and Kleckner in 1956 [2]. Schill et al offered a possible explanation of the congenital basis of a superior mesenteric vein aneurysm [3]. The portal vein is formed from portions of the right and left vitelline omphalomesenteric vein. Very early in development, the two vitelline veins are connected by bridging channels or anastomosis, which are named according to their relation with that portion of the foregut they surround, namely the future duodenum. Regression of the cranial component of the left vitelline vein, the central-ventral intervittelline anastomosis, and the caudal component of the right vitelline vein allows for a normal extrahepatic portal vein [4]. Schild et al proposed that if the right vitelline vein is not obliterated completely to the level of the caudal-ventral intervittelline anastomosis, a small diverticulum may persist that eventually develops into an aneurysm of the superior mesenteric vein.

Venous aneurysms are not common in clinical practice; most patients with intra-abdominal venous aneurysm seek medical assistance because of vague abdominal pain. Some patients may have gastrointestinal bleeding, acute venous occlusion, or pulmonary embolism [5]. The patient in our case presented with right lower quadrant abdominal pain related to colon cancer. The SMV aneurysm is an incidental finding.

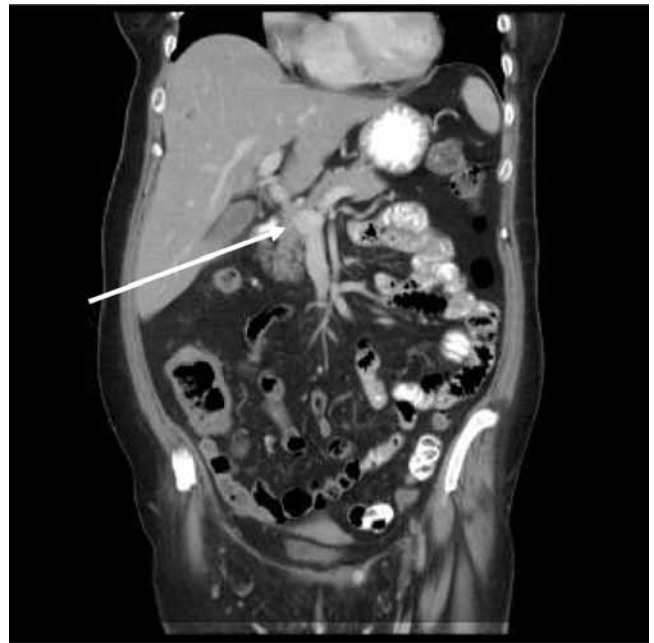
Sonography was usually the first imaging technique performed, because it is noninvasive. The aneurysm appeared as an anechoic structure near the head of the pancreas. Their vascular nature is confirmed with color Doppler and duplex sonography. Color Doppler sonography reveals that these aneurysms fill completely with color flow unless they contain thrombosis. Duplex Doppler sonography demonstrates a monophasic wave form characteristic of the superior mesenteric vein. Flow is hepatopedal in the portal vein unless there is associated portal hypertension. Flow within the superior mesenteric vein is directed toward the portal confluence.

A CT scan revealed the size and extent of the lesion, and confirmed its vascular origin, but required the use of iodinated intravenous contrast medium [6]. However, an advantage of helical CT is the CT angiogram, which allows rendering of three-dimensional angiogram images by using helical

technology and computer software. The multiplanar capability of magnetic resonance imaging (MRI) along with the capacity to render angiogram-like images of vascular structures makes MRI well suited to the evaluation of such an aneurysm. In the past,



**Figure 1.** Axial section of CT scan shows a dilated (1.8 cm AP diameter) superior mesenteric vein without internal thrombosis.



**Figure 2.** Coronal section of CT scan demonstrates a dilated superior mesenteric vein near the level of the confluence.

venous phase mesenteric angiography and splenoportography were used to evaluate these aneurysms [7, 8]. However, due to invasiveness of angiographic procedure, sonography, CT and MRI are preferred in most instances.

As there are few documented cases of SMV aneurysms, the nature and history of the disease are not clear. First-line management has changed over time, with there being a shift from surgical to conservative management. Initially it was thought that surgical intervention with either shunting or aneurysmorrhaghy procedure was the treatment of choice, particularly in cases with evidence of portal hypertension [9]. However, instead of the surgical approach, it may now be appropriate to follow up patients conservatively with serial imaging [10]. Because an SMV aneurysm is a rare anomaly and its long-term evolution is not known, patients should be clearly informed of possible complications, including rupture and thrombosis. ◆

## REFERENCES

1. Bolondi L, Gandolfi L, Arienti V, et al: Ultrasonography in diagnosis of portal hypertension: Diminished response of portal vessels to respiration. *Radiology* 1982; 142: 167-172
2. Barzilai R, Kleckner MS. Hemocholecyst following ruptured aneurysm of portal vein. *Arch Surg* 1956; 72: 725-727
3. Schild H, Schweden F, Braun B, et al. Aneurysm of the superior mesenteric vein. *Radiology* 1982; 145: 641-642
4. Marks C. surgical implications of portal venous system malformation. *Ann Coll Surg Eng* 1974; 55: 299-306
5. Nishinari K, Wolosker N, Yazbek G, Nakagawa WT, Lopes A. Idiopathic aneurysm of inferior vena cava associated with retroperitoneal ganglioneuroma: case report. *J Vas Surg* 2003; 37: 895-898
6. Seda J, Padovani B, Chanalet S. aneurysm of the superior mesenteric vein. *AJR Am J Roentgenol* 1993; 161: 903-904
7. Hagiwara H, Kasahara A, Kono M, et al. Extrahepatic portal vein aneurysm associated with a tortuous portal vein. *Gastroenterology* 1991; 100: 818-821
8. Itoh Y, Kawasaki T, Nishikawa H, et al. A case of extrahepatic portal vein aneurysm accompanying lupoid hepatitis. *J Clin Ultrasound* 1995; 23: 374-378
9. WL Perret, A de Silva, et al. Portal circulation aneurysms: Two case reviews. *Australasian Radiology* 2007; 51: 87-90
10. Fulcher A, Tumer M. Aneurysm of the portal vein and superior mesenteric vein. *Abdom Imaging* 1997; 22: 287-289

## 上腸繫膜靜脈瘤：病例報告

簡紹南<sup>1</sup> 蔣咸嘉<sup>1</sup> 陳永芳<sup>2</sup> 陳瑞芬<sup>2</sup>

大千綜合醫院 放射科<sup>1</sup>

中國醫藥大學附設醫院 放射線部<sup>2</sup>

靜脈瘤 (venous aneurysm) 在臨床實務中並不常見，因此發生個案時可作為主題發表。而上腸繫膜靜脈 (superior mesenteric vein) 的原發性靜脈瘤 (idiopathic aneurysm) 亦相當罕見，會發生在肢體不對稱或有併存疾病者身上，但病因仍不清楚。我們在本文中所探討的個案，是經 MDCT 診斷為結腸癌患者的上腸繫膜靜脈瘤。